

Airway Regional Anesthesia for Awake Fiberoptic Intubation

Shawn T. Simmons, M.D., and Arno R. Schleich, M.D.

Providing anesthetic care to the patient with a difficult airway keenly interests anesthesiologists and is a situation that often provokes much anxiety and trepidation. However, dealing effectively and safely with these patients is a skill that all anesthesiologists should be familiar with and are expected to perform with competency.

Difficult airways arise from multiple causes. Access to the oral cavity can be impeded by unfavorable anatomy, such as a small mouth or receding jaw, as well as reduced mouth opening due to radiation therapy, jaw fracture, or previous head and neck surgery. Difficulty in neck extension shows up in the patient who can't extend due to prior cervical fusion or advanced osteoarthritis. In addition, neck extension is contraindicated in patients with unstable cervical spines due to fractures, rheumatoid arthritis, Down syndrome, etc. Finally, there is a subset of patients who cannot be intubated using direct laryngoscopy due to anatomical variations, even though their airway exam appears normal.

Whether the difficult airway is a known entity or is encountered unexpectedly, the clinician must be guided by the American Society of Anesthesiology (ASA) difficult airway algorithm and other options for providing anesthesia, such as the use of the laryngeal mask airway (LMA) and/or regional techniques, should be entertained. Still, in the situation where the airway must be controlled and anesthesia must be delivered via an endotracheal route, intubation through the use of a flexible fiberoptic bronchoscope is a commonly chosen method. However, this procedure does require some form of

anesthesia. Rarely will patients allow their airways to be instrumented without it. Although fiberoptic intubation can be done under general anesthesia and may be advantageous in some situations, many believe that the use of regional anesthesia in the setting of a difficult airway is advantageous. Possible advantages include the fact that the patient is able to cooperate with the operator, is able to breathe spontaneously throughout the procedure, and is able to maintain airway patency though conscious control of the airway muscles. While there are many methods that may be used to provide anesthesia to the airway, descriptions of these methods tend to be widely scattered throughout various textbooks and journals, and the choice of which method to use is often based on limited information, such as institutional tradition and personal experience. A Medline search was performed for this review covering the last several decades and using multiple combinations and permutations of the applicable key terms. No previous articles were found that provided a comprehensive review of this subject. Therefore, in this review, we will cover the neuroanatomy of the upper airway and then describe several techniques that can be used to provide airway anesthesia for fiberoptic intubation. These techniques include methods of topically anesthetizing the airway by the use of sprays and direct application of local anesthetics to the respiratory mucosa, as well as descriptions of a variety of nerve blocks.

Innervation of the Airway

The airway is divided into the nasal and oral cavities, the pharynx (consisting of the naso-, oro-, and hypopharynx), the larynx, and trachea (Fig 1). In an awake patient, anesthesia is rarely needed for manipulation of the oral cavity and the portions of the airway anterior to the tonsillar pillars. However, it is usually necessary for any intervention affecting the remaining airway regions.

From the Department of Anesthesia, University of Iowa, Iowa City, Iowa.

Accepted for publication October 24, 2001.

Supported by departmental funds.

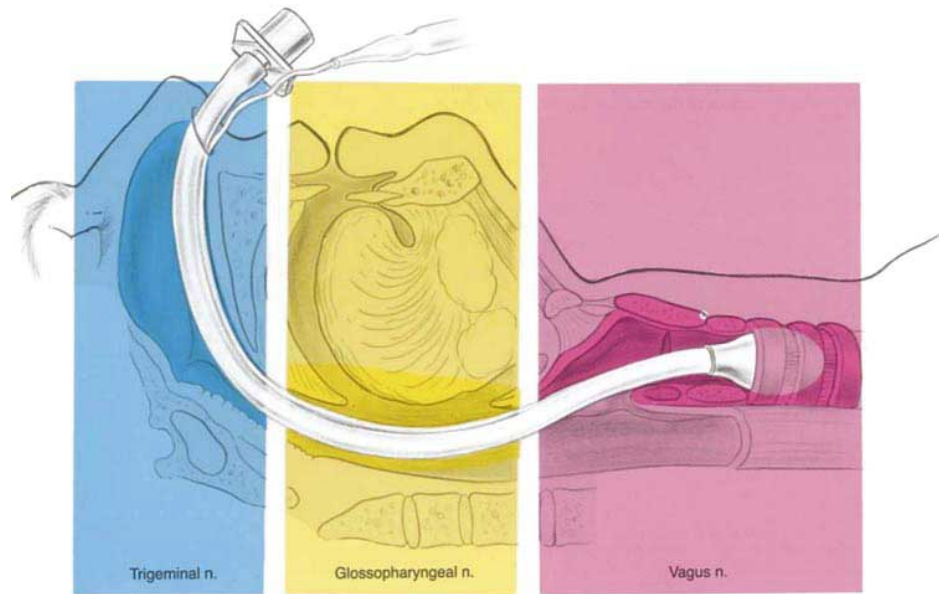
Reprint requests: Shawn T. Simmons, M.D., University of Iowa Hospitals and Clinics, 200 Hawkins Dr, Iowa City, IA 52242-1079. E-mail: shawn-simmons@uiowa.edu

© 2002 by the American Society of Regional Anesthesia and Pain Medicine.

1098-7339/02/2702-0101\$35.00/0

doi:10.1053/rapm.2002.30659

Fig 1. The innervation of the upper airway. (Reprinted with permission.³²)



Nose

The nasal cavity is entirely innervated by fibers carried by branches of the trigeminal nerve.¹ The anterior parts of the nasal cavity and the septum are supplied by the anterior ethmoidal nerve (a branch of the ophthalmic nerve), which enters the nasal cavity through the anterior ethmoidal foramen. The remaining parts of the nasal cavity and the septum are supplied by branches of the maxillary nerve,² the most prominent being the lateral posterior superior, inferior posterior, and nasopalatine nerves.

These branches are relayed through the sphenopalatine ganglion, which is situated in the pterygoid fossa lateral to the sphenopalatine foramen at the level of the crest of the superior turbinate, and carry sensory fibers of the maxillary nerve, sympathetic fibers arising from the carotid plexus and, once reaching the ganglion in the vidian nerve, a branch of the major petrosal nerve. The latter also carries parasympathetic fibers derived from communicating branches of the glossopharyngeal nerve. Finally, pharyngeal and palatine branches arising from the sphenopalatine ganglion supply the soft and hard palate and contribute to the pharyngeal plexus in the nasopharynx.

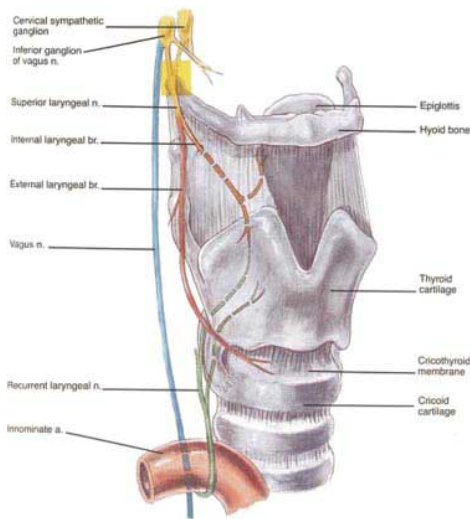


Fig 2. The vagus nerve and its branches in the larynx. (Reprinted with permission.³²)

Pharynx

Several sensory modalities are conveyed by the glossopharyngeal nerve. It provides the posterior third of the tongue, the fauces and tonsillae, epiglottis and all parts of the pharynx with visceral sensory fibers, and the posterior third of the tongue and soft palate with special visceral sensation (taste). It also carries secretomotor fibers to mucous glands in the areas supplied. Importantly, a visceral branch innervates the carotid sinus. Sympathetic fibers are derived from the carotid plexus and the cervical sympathetic trunk. Efferent motor fibers innervate the stylopharyngeus muscle and join the pharyngeal plexus. The glossopharyngeal nerve emerges at the jugular foramen and curves forward between the jugular vein and internal carotid artery. It then descends in front of the latter vessel and beneath the styloid process and its attached muscles to the inferior border of the stylopharynx-

geal muscle, which it follows a variable distance before curving medially and entering the pharyngeal muscles at the level of the middle constrictor.

The motor innervation of the pharynx receives extensive efferent input from the vagus nerve, which sends multiple branches to the pharyngeal plexus through its pharyngeal branch. It arises from the inferior ganglion located below the jugular foramen, carrying fibers from the accessory nerve.

Larynx

The origin and contributions from the accessory nerve are similar in the case of the superior laryngeal nerve (Fig 2). The superior laryngeal nerve slants forward to the cornu major of the hyoid bone before dividing into an internal and external branch. The former enters through a foramen in the thyrohyoid membrane and provides visceral sensory and secretomotor innervation to the larynx above the true cords, whereas the latter descends along the outside of the thyrohyoid membrane beneath the sternothyroid muscle to the cricothyroid muscle, which it supplies with motor fibers.

In the neck the vagus nerve descends in the carotid sheath to the thoracic inlet, at first lying behind and between the internal jugular vein and internal carotid artery, and then between the former and the common carotid artery.³ During its intrathoracic course, it gives off the recurrent laryngeal nerve, which curves around the aortic arch lateral to the ligamentum arteriosum on the left and around the subclavian artery on the right. The recurrent laryngeal nerve then ascends in a groove formed by the trachea and esophagus to the larynx, while providing both structures with fibers for visceral sensation, motor and secretomotor innervation, and sympathetic branches, which join the nerve after originating from the cervical sympathetic chain. Passing under the lower border of the inferior constrictor of the pharynx, it enters the larynx. It supplies all muscles of the larynx except the cricothyroid and conveys visceral sensation to the cords and infraglottic regions. It is the motor nerve of all intrinsic muscles of the larynx, except the cricothyroid muscle, which is supplied by the external branch of the superior laryngeal nerve. The vagus nerve then continues on its course through the thorax and supplies sensory input to the tracheal mucosa.

Airway Reflexes

The aforementioned nerves participate in several brainstem-mediated reflex arcs, the function of which is airway protection.

The gag reflex is triggered by mechanical and

chemical stimulation of areas innervated by the glossopharyngeal nerve.⁴ The efferent motor arc is provided by the vagus nerve and its branches to the pharynx and larynx. Examination of the gag reflex provides information about brainstem function and the ability to protect the airway. A selective bilateral block of the glossopharyngeal nerve can effectively abolish conduction in the afferent arc of the gag reflex.

The glottic closure reflex is another protective airway reflex.⁵ It can be elicited by selective stimulation of the superior laryngeal nerve, but has been reported to be triggered by stimulation of any cranial nerve in experimental animals. The efferent arc encompasses the superior as well as the recurrent laryngeal nerve. Exaggeration of the glottic closure reflex, called laryngospasm, may be noted after prolonged or intense stimulation of the glottis and is initiated solely by stimulation of the superior laryngeal nerve.

Cough is another important mechanism of airway protection. Cough receptors located in the larynx and trachea¹ receive afferent and efferent fibers from the vagus nerve. Chemical and mechanical stimulation triggers coughing, which may be abolished by topical anesthesia of the subglottic larynx and trachea.

Preparation of the Patient

Preparation of the patient for fiberoptic intubation is important and can greatly increase the chances of success of both providing adequate anesthesia for the procedure and in completing a smooth, atraumatic intubation. Preparation can be divided into 3 areas: explanation, sedation, and antisialagogues.

Explanation

Explanation encompasses describing to the patient the reasons for proceeding with an awake fiberoptic intubation, the potential complications, the type of airway anesthesia that will be provided, and possible alternatives to the proposed anesthetic. Many patients are apprehensive about being intubated while awake. However, a thorough discussion of the proposed procedures and reassurance that the patient will be given enough sedation to be comfortable throughout the intubation will usually allay fears and secure patient cooperation. Optimally, this discussion should be held during the preoperative evaluation so that there is plenty of time to address questions and concerns. Waiting until the last moment before the patient is wheeled into the operating room (OR) to address these issues can often provoke anxiety, rather than reduce it.

Sedation

Providing adequate sedation is important and advantageous in both the anesthetizing of the airway as well as during the intubation itself. A calm and comfortable patient is much more likely to cooperate with the anesthesiologist during these procedures, thus making the process easier and more successful. Agents used to produce sedation generally fall into 2 groups: benzodiazepines and opioids.

The benzodiazepines produce significant sedation and amnesia and can help prevent seizure activity in the event of local anesthetic toxicity. However, they are also more likely to produce unconsciousness and thus an uncooperative patient.⁶ In appropriate doses, any of the popular benzodiazepines, such as diazepam, lorazepam, and midazolam, can be used to provide sedation during fiberoptic intubation (Table 1). While normally given intravenously (IV), oral and nasal⁷ administration can be considered if enough time and monitoring are available prior to the procedure and may be useful in highly nervous, less cooperative, or pediatric patients. Nevertheless, due to its quick onset, fairly short duration of action, and lack of pain with injection,⁸ midazolam has much to recommend it, and 1 to 3 mg IV in the average sized adult, especially when combined with other agents, is usually enough to produce a comfortable, cooperative patient.

Opioids are also useful by providing analgesia and can help blunt airway reflexes, especially coughing. However, they do not provide amnesia and can cause significant respiratory depression. In spite of this respiratory depression, opioids are not as likely to produce unconsciousness, and apneic patients will often breathe if instructed.⁹ Again, all the popular opioids, including morphine, meperidine, alfentanil, sufentanil, and fentanyl, can be used in this context (Table 2). IV administration is the most common, but intramuscular (IM) administration can be considered, especially with morphine and meperidine. In addition, oral/transmucosal preparations of fentanyl are available that may be of use in the pediatric population.¹⁰ Morphine produces good analgesia and is readily available, but can

Table 1. Pharmacology of Benzodiazepines

	Equivalent Dose (mg/kg)	Clearance (mL/kg/min)	Elimination Half-Time (hr)
Diazepam	0.3-0.5	0.2-0.5	21-37
Midazolam	0.15-0.3	6-8	1-4
Lorazepam	0.05	0.7-1	10-20

Adapted and reprinted.³³

Table 2. Pharmacology of Opioids

	Equivalent Potency	Clearance (mL/kg/min)	Elimination Half-Time (min)
Morphine	1	15-23	114
Meperidine	0.1	10-17	180-264
Fentanyl	75-125	11-21	185-219
Sufentanil	500-1,000	13	148-164
Alfentanil	25	5-7.9	70-98

Adapted and reprinted.³⁴

cause some hypotension due to histamine release. Meperidine has been reported to produce a euphoric feeling (similar to morphine), but should be used with caution in patients with reduced renal function due to its renally cleared metabolites.¹¹ Alfentanil and sufentanil are both associated with hemodynamic stability, are relatively short acting, and produce excellent analgesia, but are more expensive than other agents. In addition, due to its high potency,¹² sufentanil can be difficult to titrate without producing excess sedation and respiratory depression. Fentanyl, with its relative hemodynamic stability,¹³ low cost, and familiarity to most anesthesiologists, is frequently used, and small doses (0.5 to 2 $\mu\text{g}/\text{kg}$) are usually enough to produce the desired effect.

One should remember that the benzodiazepines and opioids are synergistic in their actions and in combination can produce excess sedation at lower than expected doses.¹⁴ Thus, titration to effect while closely monitoring the patient's level of consciousness and respiratory function is important. A commonly observed practice is to give 1 to 2 mg of midazolam IV at the start of the procedure and then to titrate fentanyl as needed.

If excess sedation becomes a problem, the use of opioid and benzodiazepine antagonists may be useful. Naloxone, a relatively pure opioid antagonist, can be given either IV or subcutaneously. Small doses (0.04 to 0.4 mg) can be titrated to reverse central nervous system (CNS) and respiratory depression. However, it must be used with caution in opioid-dependent patients, as its use can precipitate withdrawal. In addition, due to its short duration of action (1 to 4 hours), there is the possibility that excess sedation can reoccur when this drug wears off.¹⁵ Similarly, the specific benzodiazepine antagonist, flumazenil, can be used to reverse excess sedation due to benzodiazepines. This drug is administered IV in divided doses over 1 to 10 minutes to a total dose of 5 mg. Again, flumazenil should be used with caution, as it has been associated with the production of seizures. It, as well, has a short duration of action (30 to 60 minutes) and may need to be redosed.¹⁶

Table 3. Comparative Effects of Anticholinergic Drugs

	Sedation	Antisialagogue	Increase Heart Rate
Atropine	+	+	+++
Scopolamine	+++	+++	+
Glycopyrrolate	0	++	++

NOTE. 0 = none, + = mild, ++ = moderate, +++ = marked. Adapted and reprinted.¹⁷

Antisialagogues

Antisialagogues are useful in 2 ways. First, decreasing oral secretions will aid in the placing and effectiveness of topical agents. Second, fiberoptic intubation is much easier if excess secretions are not obscuring the operator's view. While any anticholinergic agent, such as atropine or scopolamine, could be given for this purpose, glycopyrrolate is the one that is most commonly used due to its lack of CNS effects and relatively lesser likelihood of producing tachycardia (Table 3). In normal adults, 0.2 mg of glycopyrrolate IV/IM is usually enough to produce clinically acceptable results. However, if the IM route is chosen, it must be administered earlier, as it takes approximately 15 minutes for peak plasma concentrations to occur.¹⁷

Local Anesthetics

While any local anesthetic can theoretically produce airway anesthesia for fiberoptic bronchoscopy, the 3 most often used are cocaine, benzocaine, and lidocaine, with or without the use of vasoconstrictors (Table 4).

Cocaine

Cocaine was the first local anesthetic discovered and is unique in having intrinsic vasoconstrictor properties, especially when applied to mucous membranes.¹⁸ Thus, in a 4% solution, it is useful for fiberoptic intubation, particularly when a nasal intubation is planned, as it provides both anesthesia and can help control the bleeding that frequently accompanies instrumentation of the nasal passages. However, there are difficulties associated with its

use, including possible adverse effects (tachycardia, hypertension, dysrhythmias, and seizures), potential for abuse, and severely restricted availability.¹⁸ Thus, while effective when used appropriately, cocaine must be used with caution.

Benzocaine

Benzocaine is a water-insoluble ester local anesthetic that is frequently used in a 20% spray to produce anesthesia in mucous membranes. Advantages are that it is readily available in commercially prepared aerosol applicators, it is easy to apply to the oral mucosa, and it produces anesthesia in 15 to 30 seconds. Benzocaine is relatively short-acting and has a duration of 5 to 10 minutes. Although this duration of action is enough for most cases, it may not be adequate in prolonged procedures. Its major disadvantage is that it is associated with the production of methemoglobinemia after as little as a total of 4 seconds of spraying.¹⁸ Therefore, it should be used sparingly and with methemoglobin production in mind.

Lidocaine

Lidocaine was the first clinically used amide local anesthetic and has become the most widely used local anesthetic in the world.¹⁹ It is available in many concentrations (0.5% to 10%) and many forms (liquid, ointments, creams, etc.). Its advantages include ready availability, relatively low CNS and cardiac toxicity, reasonably quick onset, and clinically useful duration of action (30 to 60 minutes after topical application and 1 to 2 hours after infiltration). Generally, 1% to 2% solutions are used for infiltration and nerve block, while 2% to 4% solutions are used for topical application. However, one must be careful when using this agent, as it is quickly absorbed from oral and tracheal mucosa and toxic plasma levels ($>5 \mu\text{g}/\text{mL}$) can be reached when even moderate amounts of high concentration solutions are used. In addition, caution must be used in patients with hepatic dysfunction, as lidocaine is primarily eliminated in the liver.¹⁸

Table 4. Comparison of Local Anesthetics

	Clinical Use	Onset	Clinical Duration (min)	Recommended Maximum Adult Dose
Cocaine	Topical	Slow	30-60	100 mg (1.5 mg/kg)
Benzocaine	Topical	Fast	5-10	200 mg
Lidocaine	Topical	Moderate	30-60	300 mg without epinephrine (4 mg/kg)
	Nerve block	Fast	60-180	500 mg with epinephrine (7 mg/kg)

Adapted and reprinted.¹⁸

Vasoconstrictors

Vasoconstrictors are sometimes used as adjuncts to local anesthetics. Epinephrine (normally in a concentration of 1:200,000) added to lidocaine has several theoretical advantages. It helps to prolong the duration of nerve blocks, and, when applied topically, causes mucosal vasoconstriction, which improves visualization during the procedure and helps limit bleeding. For the same reasons, 0.125% to 0.5% phenylephrine²⁰ and 0.05% oxymetazoline (Afrin; Schering-Plough Corp, Kenilworth, NJ)²¹ are often applied to the nasal mucosa prior to a nasal intubation to shrink the mucosa and limit bleeding. However, caution must be used when these agents are applied to mucous membranes, as they can be rapidly absorbed systemically, leading to adverse hemodynamic effects, such as hypertension and tachycardia (epinephrine) or bradycardia (phenylephrine and oxymetazoline). Since the duration of nerve block provided by plain lidocaine is usually sufficient for most fiberoptic intubations, epinephrine-containing solutions are generally not needed. However, the topical application of phenylephrine and oxymetazoline to the nasal mucosa is frequently effective in this setting.

Topical Anesthesia: Spraying

Topical anesthesia of the airway mucosa is generally accomplished by either some form of spraying of a local anesthetic solution onto the respiratory mucosa or by applying it directly to the mucosa itself. Spraying of local anesthetic can be accomplished in several ways, including the use of commercially prepared aerosol spray cans, atomizers, and nebulizers. It should be noted that the terms atomizer (a device used to reduce liquid medications to fine particles in the form of a spray or aerosol; useful in delivering medicines to the nose and throat) and nebulizer (a device used to reduce liquid medicines to extremely fine cloud-like particles; useful in delivering medication to deeper parts of the respiratory tract)²² are essentially synonyms. However, in the following descriptions, the term atomizer is used to denote a device in which a local anesthetic spray is produced intermittently and actively directed onto the mucosa by the operator, while the term nebulizer is used to describe a device whereby the anesthetic is converted into a mist, which is then inhaled by the patient.

Aerosol Sprays

Commercially available aerosol cans of benzocaine (Hurricane Spray; Beutlich Pharmaceuticals, Waukegan, IL) are popular. These cans are supplied

with several disposable red plastic tubes that allow for accurate direction of the spray and minimize the risk of cross-contamination between patients. Because of their ready-to-use and self-contained nature, they are quick and convenient to use. However, most patients find the taste of the solution unpleasant and unintentional aspiration of the spray often provokes severe coughing and gagging. Asking the patient to hold his or her breath during the application of the local anesthetic can minimize this. Generally, 3 applications with a duration of approximately 1 second each (with an appropriate rest period between the sprays) is sufficient.

Atomizer

Lidocaine is frequently sprayed on the mucosa using an atomizer device (Fig 3). Two methods can be used. Both involve removing the rubber bulb from a standard atomizer and using a length of oxygen tubing to connect the atomizer to the auxiliary oxygen outlet on the anesthesia machine, which is set at a flow rate of 8 to 10 lpm. In the first method, a small hole is cut into the top of the tubing and the reservoir is filled with lidocaine. When the operator's thumb is placed over the hole in the tubing, a near constant and thick spray of local anesthetic is produced that can be directed easily into the posterior pharynx. A disadvantage of this method is that it is difficult to accurately deliver a known volume of local anesthetic to the mucosa. The second method allows for a more controlled dose of lidocaine to be administered. In this method, the reservoir is removed and a 5- to 10-cc syringe is connected to the atomizer's intake tube via a pediatric IV t-tube adapter. Injecting small aliquots of lidocaine through the IV adapter then produces the spray. This allows for precise dosing and timing of the lidocaine spray. In both methods, it is useful to have the patient pant while the spray is being applied, as this tends to draw the local anesthetic into the hypopharynx, larynx, and upper trachea. When used as the sole anesthetic, these methods provide good anesthesia of the oral, pharyngeal, and laryngeal mucosal, but often do not provide adequate coverage of the trachea.

Another atomizer-like device, which can be used to spray local anesthetic onto the respiratory mucosa, is the MAD (Mucosal Atomization Device), which is manufactured by Wolfe Troy Medical, Inc, of Salt Lake City, UT. This small device has a spray nozzle at the distal end and is designed to be connected to a liquid-filled syringe. When the plunger of the syringe is depressed, the liquid is sprayed out in a fine mist and can be directed onto the target mucosa. In a second version of this device, the spray

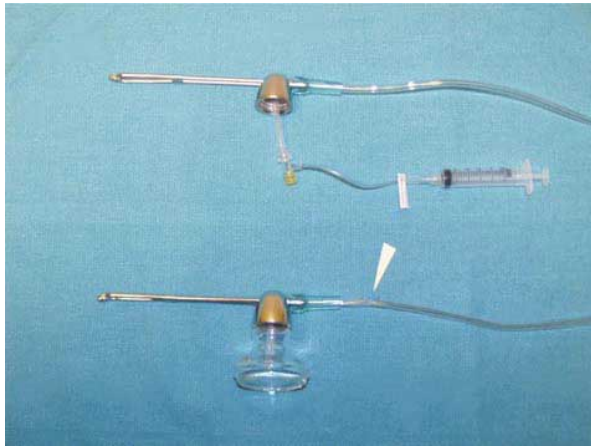


Fig 3. Typical atomizer set ups with oxygen tubing. Arrow points to a thumb-hole cut into the top of the oxygen tubing.

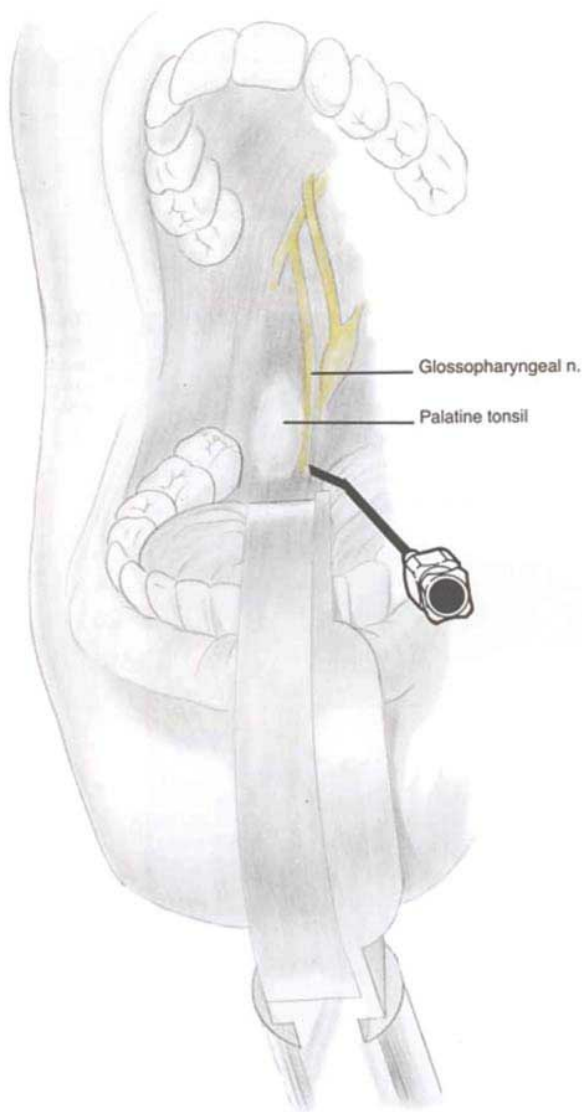


Fig 5. Intraoral approach to the glossopharyngeal nerve. (Reprinted with permission.²⁸)

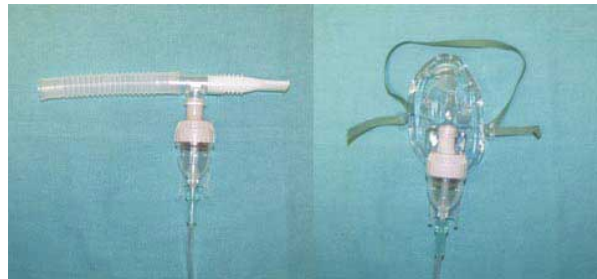

Fig 4. Typical nebulizers. Mouthpiece type on left, face-mask type on right.

nozzle is attached at the end of a 6-inch malleable tubing extension that is bent at various angles to facilitate the spraying of the posterior oropharyngeal cavity.

Nebulizer

Local anesthetic can also be applied to the nasopharyngeal and laryngeal mucosal via nebulization (Fig 4). In general, approximately 4 mL of 4% lidocaine is placed in a standard breathing treatment nebulizer and the patient inhales the vapor. If

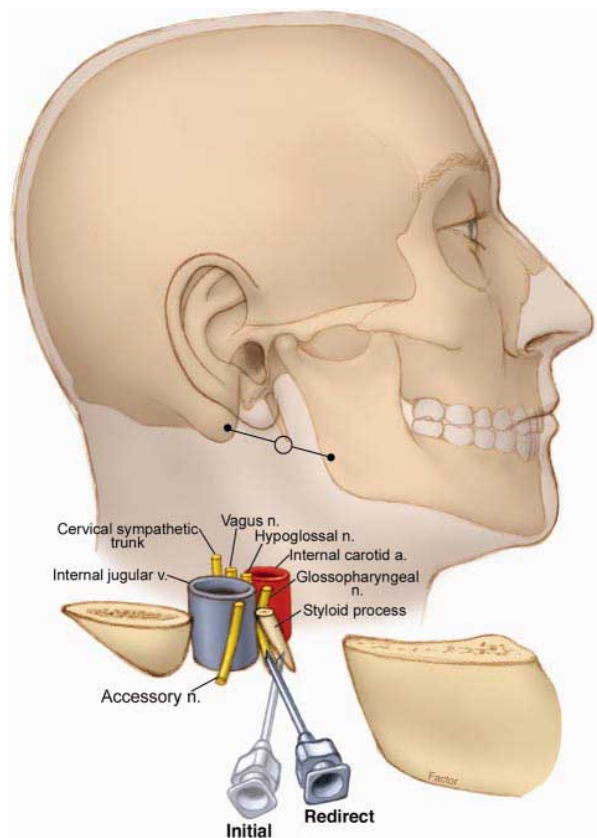


Fig 6. Peristyloid approach to the glossopharyngeal nerve. (Adapted and reprinted with permission.²⁸)

a nasal intubation is planned, a face mask nebulizer can be used with patients being instructed to breathe through their nose. If an oral intubation is desired, a face mask or mouthpiece nebulizer can be used. Kunda et al.²³ compared nebulization of 4 mL of 4% lidocaine via face mask against a method which consisted of combined upper airway nerve blocks (superior laryngeal and translaryngeal) along with direct application of lidocaine to the nasal mucosa with cotton-tipped swabs. They found that while the combined nerve block technique did provide better patient comfort and hemodynamic stability, both techniques provided satisfactory intubating conditions. In another study, Mostafa et al.²⁴ also obtained good results when using nebulized lidocaine. They, however, used 6 mg/kg of a 10% solution. The authors of both of these reports recognized that toxic plasma levels of lidocaine during nebulization are possible due to the relatively large amounts of concentrated solutions used. However, no patient in either study showed evidence of elevated plasma lidocaine concentrations. This was felt to be due to the belief that a large amount of the drug is lost during exhalation.

Topical Anesthesia: Direct Application

The nasal, oropharyngeal, and tracheal mucosa can also be anesthetized by direct application of local anesthetics to these tissues. These methods include placing local anesthetics in the nose via the use of cotton-tipped swabs or nasopharyngeal airways and applying anesthetizing agents to the orotracheal structures by the use of gargling, aspiration, indirect laryngoscopy, and via the fiberoptic bronchoscope itself.

Nose

If nasal intubation is planned, 2 methods of applying local anesthetics are popular. The first is to use cotton-tipped swabs soaked in either lidocaine or cocaine. The swabs are placed superiorly and posteriorly in the nasopharynx and left for several minutes to block the branches of the ethmoidal and trigeminal nerves.²³ The other method involves coating a nasopharyngeal airway with viscous lidocaine mixed with a vasoconstrictor (usually phenylephrine) and gently inserting the airway into the nares. After several minutes, progressively larger airways, coated with the lidocaine mixture, can be introduced until an airway of approximately the same size as the planned endotracheal tube is in place. This method not only allows for prelubrication of the nasal passages with a vasoconstricting solution, but also ensures that these passages are patent and likely large enough for the endotracheal

tube. Although the initial placement of the nasal airway can cause some discomfort, it is usually mild and well tolerated by the patient.

Gargling

For oral intubation, gargling of local anesthetic solutions is often used to provide anesthesia to the oral and pharyngeal tissues. Most commonly, several milliliters of a 2% to 4% lidocaine solution are placed in the patient's mouth, and the patient is instructed to gargle with this solution. The solution is then expectorated to avoid excess local anesthetic absorption. While this method can provide adequate anesthesia to the oral mucosa, it does not often cover the larynx or trachea adequately, and other methods must be used to anesthetize these structures.

Aspiration

An interesting investigation of anesthetizing the airway by aspiration of lidocaine has been published by Chung et al.²⁵ Their method involved the slow dripping of an anesthetic solution onto the tongue of a supine subject. First, two 5-cc aliquots of 2% lidocaine were gargled for 1 minute each. This was then followed by a slow and steady trickling of 0.2 mL/kg (max 20 cc) of 1.5% lidocaine onto the posterior portion of the tongue while it was being manually pulled forward. The authors found that the initial few milliliters of fluid flowed into the vallecula, around the base of the epiglottis, and reached the piriform sinus. After initial swallowing subsided, the lidocaine solution then flowed over the arytenoid notch and past the cords into the trachea. This flow did cause some mild coughing, but was otherwise well tolerated. In their study, 39 patients requiring awake fiberoptic intubation were recruited. It was found that all the patients tolerated instrumentation of their airways without supplemental lidocaine, and only 1 reacted to the presence of the endotracheal tube with more than mild coughing and gagging. In addition, no statistically significant hemodynamic changes from baseline were noted, and no subject showed signs of local anesthetic toxicity. The authors concluded that this is a simple, safe, and effective method of anesthetizing the upper airway. However, they did note that retraction of the tongue was key, as it prevented adequate swallowing and facilitated the aspiration of the lidocaine.

Another method of placing lidocaine on the back of the tongue and allowing it to be aspirated can also be utilized. In this method, viscous lidocaine or 5% lidocaine ointment is placed on the end of a tongue depressor. The tongue depressor is then in-

serted into the mouth and inverted so that the lidocaine is placed in contact with the posterior part of the tongue. The patient is then instructed to hold the tongue depressor in the mouth much like a lollipop. The patient is encouraged not to swallow, but to let the lidocaine “melt” and run down the tongue. Much like above, the lidocaine eventually numbs the posterior pharynx and is aspirated into the trachea, as evidenced by the patient suffering some mild coughing spells.

Indirect Laryngoscopy

A method of topical anesthesia for the glottis that is popular in bronchoscopy suites involves the use of indirect laryngoscopy.²⁶ In this method, the oral mucosa is numbed by the use of anesthetic sprays and/or gargling with local anesthetic. The patient or an assistant is then asked to grasp the tongue with gauze and retract it forward. A light source (such as a headlight) is then used in conjunction with an angled indirect laryngeal mirror to visualize the vocal cords and glottic structures. A syringe with a curved metal cannula is then used to apply local anesthetic to the glottis and into the trachea under indirect visualization in the mirror. This method often provides adequate anesthesia to the glottis and upper trachea that can then be supplemented with additional aliquots of local anesthetic injected through the fiberoptic scope as needed.

Fiberoptic Bronchoscope

The fiberoptic bronchoscope itself can be used to apply local anesthetic to the respiratory mucosa.²⁷ Once the nasal and/or oral mucosa is anesthetized by any of the preceding methods, the fiberoptic scope is advanced to a position in the hypopharynx where the epiglottis, cords, and other glottic structures can be clearly visualized. At this point, aliquots of local anesthetic can be injected through the working channel of the scope and onto the target mucosa. Most commonly, 1 milliliter of 2% lidocaine is drawn into a non-Luer-locked 10-mL syringe. The plunger is then drawn back to the 10-mL mark so that when the syringe is inverted and the tip is inserted into the working channel port, there is a 9-mL column of air on top of the 1 cc of local anesthetic. This way, when the syringe’s plunger is fully depressed, the liquid is fully dispelled from the working channel by the following air. In fact, a second 10 mL of air is often injected immediately after the first in order to ensure that all of the solution has been ejected. While the local anesthetic is being injected, it is helpful to clamp off or otherwise kink the suction tubing connected to the scope to avoid losing any of the local anesthetic

solution via this route. This procedure can be repeated several times until adequate anesthesia of the glottis is obtained. The scope is then advanced through the glottis into the larynx and trachea with pauses to inject further aliquots of local anesthetic as needed to provide anesthesia to the remaining airway. Of note, suctioning should be avoided as much as possible during application of the local anesthetic to allow for maximum time of contact between the local anesthetic and mucosa. It is often most efficient to have an assistant inject the local anesthetic and kink the suction tubing while the operator controls the scope and directs the stream of local anesthetic. With experience and a good understanding of the relationship between the bronchoscope’s fiberoptic and working channels, this stream of local anesthetic can be directed with a great deal of accuracy.

Nerve Blocks

Nerve blocks are often used to provide anesthesia for awake fiberoptic intubation. While these blocks are often more technically difficult to perform and generally carry a higher risk of complications (including bleeding, nerve damage, and intravascular injection) than the above mentioned noninvasive methods, in experienced hands they are useful and provide excellent anesthesia and intubating conditions. As detailed earlier, the glossopharyngeal nerve provides sensation to the oropharynx including the posterior portion of the tongue and is involved in the gag reflex, while the vagus supplies the larynx and trachea, with its superior laryngeal branch providing sensation to the structures above the cords. Therefore, 3 blocks are used to provide anesthesia to the upper airway: glossopharyngeal (oropharynx), superior laryngeal (larynx above the cords), and translaryngeal (larynx and trachea below the cords).

Glossopharyngeal Block

This block can be performed by using 2 different approaches: intraoral and peristyloid.²⁸ If the intraoral approach is desired, the patient must have enough mouth-opening ability so that the base of the posterior tonsillar pillar can be visualized. In addition, adequate topical anesthesia must be provided to the tongue and tonsillar mucosa so that the patient will allow manipulation of this sensitive area. The peristyloid approach does not require mouth opening, but does require access to the lateral neck and the ability to distinguish the bony landmarks. For both approaches, careful aspiration for blood must be carried out prior to injection because the glossopharyngeal nerve is closely asso-

ciated with the internal carotid artery in these locations and even a very small amount of local anesthetic injected into this vessel can cause seizures.

For the intraoral approach (Fig 5), the patient is placed in whatever position allows for the best view of the base of the posterior tonsillar pillars (usually semireclined). After sufficient topical anesthesia is applied, the tongue is displaced in an anteroinferior direction to allow visualization of the pillar. A laryngoscope blade, such as a Macintosh no. 3, is useful for this, as it provides both retraction and additional light, which makes the identification of the structures easier. The tip of a 22- or 25-gauge sharp bevel (Quincke) spinal needle is then advanced into the submucosal tissues at the caudal aspect of the posterior tonsillar pillar. After careful aspiration, 5 mL of local anesthetic is then injected in this area. Bending the distal centimeter of the needle at approximately a 45° angle facilitates this submucosal injection. The procedure is then repeated on the contralateral side. Because of its submucosal location, an alternative approach to blocking this nerve is to firmly apply a local anesthetic-soaked gauze pad in this same area using a right-angle clamp. The gauze is held for several minutes and then removed. While this approach is not always as successful as injecting the local anesthetic, it does avoid the possibility of intravascular injection.

For the peristyloid approach (Fig 6), the patient is placed in a supine position with the head in a neutral position. The styloid process is then located by drawing a line between the tip of the mastoid process and the angle of the jaw. The styloid process should lie under the midpoint of this line, which can be confirmed by deep palpation with a finger (this can be uncomfortable for the patient). After a skin wheal is placed, a 22-gauge needle is inserted at the midpoint of the line, perpendicular to the skin, until the styloid process is contacted, generally after less than 1 to 2 cm. The needle is then redirected posteriorly until it is walked off the styloid process. As soon as contact is lost, the needle is aspirated, and 5 to 7 mL of local anesthetic is injected. The process can then be repeated on the contralateral side.

Superior Laryngeal

The superior laryngeal nerve is blocked where it runs between the greater cornu of the hyoid bone and the superior cornu of the thyroid cartilage just before it penetrates the thyrohyoid membrane²⁹ (Fig 7). Performing this block requires some degree of neck extension, access to the anterior and lateral neck, and the ability to identify the aforementioned

structures. Identification of the hyoid bone can be difficult, especially in short, thick, or edematous necks, but is facilitated by the fact that it does not articulate with any other bones and is thus fairly mobile. Nevertheless, care must be exercised when attempting to palpate this bone, as it can be easily fractured if excess pressure is applied, particularly when the thumb and index finger of the palpating hand are used to “pinch” the hyoid between them. Other potential complications include intravascular injection and placement of the needle into the interior of the larynx. These complications, however, can be avoided with experience and careful aspiration for blood or air prior to injection and are relatively infrequent and seldom cause long-term problems.

The patient is placed in a supine position with the head maximally extended in a midline position. The hyoid bone is then firmly displaced toward the side to be blocked (which is often a bit uncomfortable for the patient). The greater cornu is identified and a 25-gauge needle is advanced until it makes contact with this structure. The needle is then walked off the bone inferiorly and then advanced 2 to 3 mm more so that the tip rests between the thyrohyoid membrane laterally and the laryngeal mucosa medially. After negative aspiration, 2 to 3 mL of local anesthetic is then injected, and an additional 1 mL is injected as the needle is withdrawn.²⁹ Alternatively, if the hyoid is difficult to identify, the needle can be walked cephalad off the superior cornu of the thyroid cartilage. It is also possible to identify the thyrohyoid membrane itself in this area and insert the needle directly through it, relying on the feeling of resistance as the needle punctures the membrane to indicate when the local anesthetic should be injected. This last method, however, does not produce as reliable results as the first two.³⁰

Translaryngeal

While this procedure is not strictly a peripheral nerve block and is more correctly described as a method of topically applying local anesthetic to the trachea and larynx, it is invasive and does carry more potential risk than other topical methods. It is therefore often grouped with the nerve blocks. This block provides anesthesia to the infraglottic larynx and upper trachea and can even provide some anesthesia to supraglottic structures, as some of the local anesthetic is coughed out of the trachea immediately following injection. However, supraglottic coverage is spotty and is most often inadequate for fiberoptic intubation. Performance of this block requires access to the anterior neck and some extension of the head so that the cricothyroid mem-

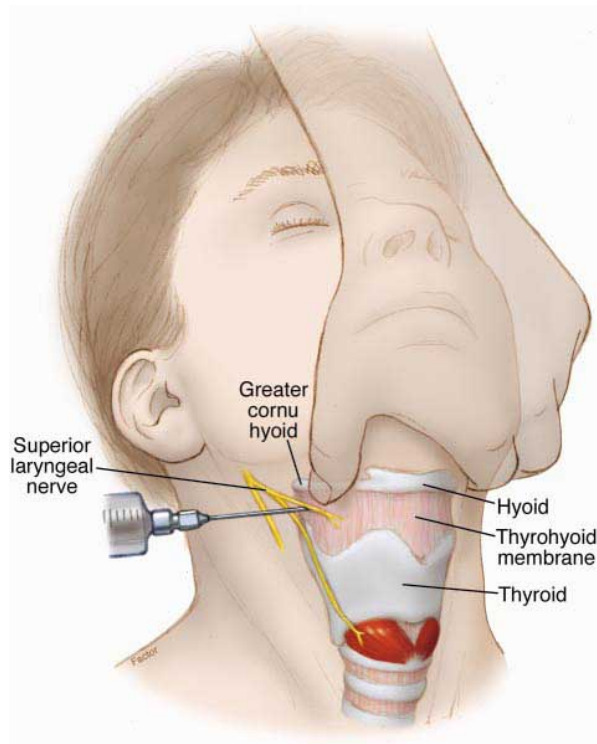


Fig 7. Superior laryngeal nerve block. (Adapted and reprinted with permission.²⁹)

brane can be identified. This block can also be somewhat difficult to perform if the patient's neck anatomy is such that the midline of the membrane, or even the membrane itself, is troublesome to locate. This is particularly important due to the fact that even though the midline of the cricothyroid membrane is relatively avascular, significant arterial and venous structures can be contacted if even seemingly minor lateral misplacement of the needle occurs. Other potential complications of this procedure include bleeding, which could lead to hematoma formation (subcutaneously or submucosally) and subsequent possible airway compromise, and puncture or laceration of the membranous portion of the trachea with possible damage to deeper structures. Translaryngeal application of local anesthetic should be used with caution in patients in whom significant coughing is undesirable, since the injection of the local anesthetic solution generally incites powerful coughing, and those who are at high risk of gastric aspiration due to the fact that the cough reflex will be greatly impaired once the tracheal mucosa is anesthetized.³¹ In spite of all this, when this procedure is performed by experienced personnel on appropriate patients, it is well tolerated, safe, and produces good results.

To perform the block, the patient is placed in a

supine position with the neck extended. The cricothyroid membrane is then located by palpating the thyroid cartilage and following it caudally until the membrane is detected in the space between the thyroid and cricoid cartilages. The midline of the membrane is then located. It is helpful to "mark" this spot by placing the index and middle fingers of the nondominant hand on either side of this location (Fig 8). A skin wheal is placed and a 20- or 22-gauge needle connected to a 5- to 10-mL syringe containing 3 to 5 mL of local anesthetic (most often 4% lidocaine) is then advanced almost perpendicularly to the skin while being aspirated. Penetration of the membrane and entry into the airway are confirmed by free aspiration of air. Care must be used to avoid inserting the needle too far and puncturing the posterior laryngeal structures. If a standard metal needle is being used, the local anesthetic solution must be injected quickly and the needle removed immediately to prevent injury of the airway by the sharp bevel as the patient coughs. Another approach is to use an IV catheter-over-needle assembly and once air is aspirated, advance the catheter off the needle and then remove the needle, leaving only the softer plastic catheter in the airway. It is recommended that an additional syringe containing a few milliliters of saline be used for this initial accessing of the airway instead of the syringe containing the local anesthetic. This is because it is easier to appreciate the aspirated air as it bubbles through a liquid rather than relying on a "loss of vacuum" feeling in an empty syringe, and discarding this whole needle/syringe assembly after placement of the catheter avoids excess manipulation of a contaminated needle. Again, care must be used to

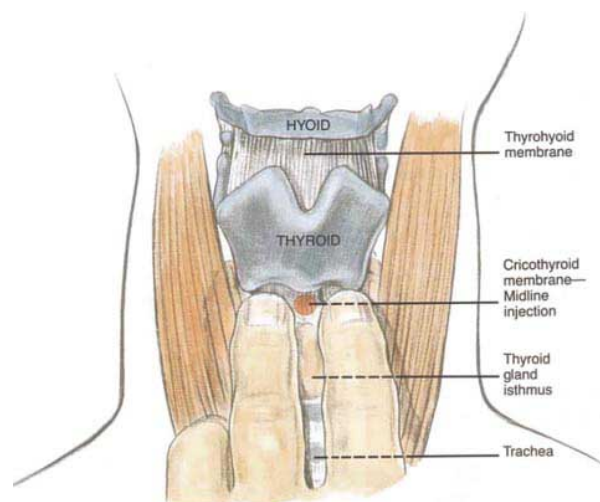


Fig 8. Translaryngeal block. (Reprinted with permission.³¹)

avoid inserting the catheter too far, as even the catheter itself has the potential to cause damage. In addition, if the tip of the catheter contacts the posterior wall of the larynx, it can provoke coughing and prevent the reaspiration of air, which is used to confirm the intraluminal position of the catheter after the syringe of local anesthetic is connected to the catheter. Once the local anesthetic-containing syringe is attached and intraluminal position is confirmed by continued free aspiration of air, the local anesthetic can then be injected into the airway. Just before injection, it is helpful to ask the patient to forcefully exhale. This forces the patient to inhale prior to coughing, which enhances the spread of the local anesthetic into the deeper airways.³¹ At this point, the catheter can either be removed, or it can be left in place as a marker to confirm entry of the bronchoscope into the trachea rather than the esophagus when the catheter is viewed through the scope during the intubation procedure.

Conclusion

The anesthesiologist who is contemplating an awake fiberoptic intubation has a variety of options. Choices must be made as to which route to use (oral or nasal), sedation for the patient, and which of the various methods of providing airway regional anesthesia, alone or in combination, is to be employed. Overall, providing topical anesthesia to the nasal and/or oral mucosa in combination with a method to anesthetize the laryngeal/tracheal structures is the most effective and the most commonly chosen plan. However, each case is different and the anesthesiologist must weigh the risks and benefits of all the methodologies to arrive at the plan that is optimized for that particular patient. Another caveat is that many of these modalities, especially the nerve blocks, do require some degree of practice before the clinician can become proficient in their use. It is prudent to obtain this practice in controlled conditions while under the tutelage of a person familiar with their application. Trying to perform an unfamiliar procedure in an emergent situation is at the very least inadvisable and may even be dangerous. In addition, while it might be attractive to use a combination of several of these techniques at the same time to provide as much anesthesia as possible, this temptation must be tempered with the knowledge that local anesthetics are absorbed very rapidly from the respiratory mucosa and toxic levels may be approached. Finally, as in all anesthetic practice, backup plans must be in place in the event that the chosen techniques are ineffective or, in the worst-case scenario, the airway is lost. Again, familiarity with the ASA difficult airway algorithm is

mandatory. Notwithstanding the above cautions, the ability to intubate via the use of a flexible fiberoptic bronchoscope in an awake patient is a very useful and necessary skill and the provision of carefully and rationally chosen airway regional anesthesia techniques makes this an effective and comfortable procedure.

References

1. Netter FH, Mitchell GAG. Cranial nerves. In Brass A, Dingle RV, eds. *Ciba Collection of Medical Illustrations, Volume I: The Nervous System, Part 1: Anatomy and Physiology*. West Caldwell, NJ: Ciba Pharmaceuticals Company; 1983:90-109.
2. Berry M, Bannister LH, Staudung SM. Nervous system. In Gray H, ed. *Gray's Anatomy*. 38th ed. London, UK: Churchill Livingstone; 1995:1249-1253.
3. Armstrong WB, Netterville JL. Anatomy of the larynx, trachea, and bronchi. *Otolaryngol Clin North Am* 1995;26:685-699.
4. Hermanowicz N, Turong DT. Cranial nerves IX (glossopharyngeal) and X (vagus). In Goetz C, ed. *Textbook of Clinical Neurology*, 1st ed. Philadelphia, PA: Saunders; 1999:206-207.
5. Petecu LG, Sasaki CT. Laryngeal anatomy and physiology. *Clin Chest Med* 1991;12:415-423.
6. Benzodiazepines. In Stoelting RK, ed. *Pharmacology and Physiology in Anesthetic Practice*, 2nd ed. Philadelphia, PA: Lippincott; 1991:118-119.
7. Ljungman G, Kreuger A, Andreasson S, Gordh T, Sorensen S. Midazolam nasal spray reduces procedural anxiety in children. *Pediatrics* 2000;105:73-78.
8. Intravenous anesthetics. In Stoelting RK, Miller RD, eds. *Basics of Anesthesia*, 4th ed. Philadelphia, PA: Churchill Livingstone; 2000:67-68.
9. Reisine T, Pasternak G. Opioid analgesics and antagonists. In: Hardman JG, Limbird LE, eds. *Goodman and Gilman's: The Pharmacological Basis of Therapeutics*, 9th ed. New York, NY: McGraw-Hill; 1996:529-531.
10. Bailey PL, Egan TD, Stanley TH. Intravenous opioid anesthetics. In: Miller RD, ed. *Anesthesia*, 5th ed. Philadelphia, PA: Churchill Livingstone; 2000:341-343.
11. Reisine T, Pasternak G. Opioid analgesics and antagonists. In: Hardman JG, Limbird LE, eds. *Goodman and Gilman's: The Pharmacological Basis of Therapeutics*, 9th Ed. New York, NY: McGraw-Hill; 1996:527-543.
12. Opioid agonists and antagonists. In Stoelting RK, ed. *Pharmacology and Physiology in Anesthetic Practice*, 2nd ed. Philadelphia, PA: Lippincott; 1991:88-89.
13. Opioid agonists and antagonists. In Stoelting RK, ed. *Pharmacology and Physiology in Anesthetic Practice*, 2nd ed. Philadelphia, PA: Lippincott; 1991:85-88.
14. Bailey PL, Pace NL, Ashburn MA, Moll LW, East KA, Stanley TH. Frequent hypoxemia and apnea after sedation with midazolam and fentanyl. *Anesthesiology* 1990;73:826-830.
15. Reisine T, Pasternak G. Opioid analgesics and antagonists. In: Hardman JG, Limbird LE, eds. *Goodman*

- and Gilman's: *The Pharmacological Basis of Therapeutics*, 9th ed. New York, NY: McGraw-Hill; 1996:549-551.
16. Hobs WR, Rall TW, Verdoorn TA. Hypnotics and sedatives; ethanol. In: Hardman JG, Limbird LE, eds. *Goodman and Gilman's: The Pharmacological Basis of Therapeutics*, 9th ed. New York, NY: McGraw-Hill; 1996:372-373.
 17. Anticholinergic drugs. In Stoelting RK, ed. *Pharmacology and Physiology in Anesthetic Practice*, 2nd ed. Philadelphia, PA: Lippincott; 1991:244-245.
 18. Ereth MH, Stubbs SE, Lennon RL. Bronchoscopic pharmacology and anesthesia. In: Prakash UBS, ed. *Bronchoscopy*, 1st ed. Philadelphia, PA: Lippincott-Raven; 1997:97-98.
 19. Local anesthetics and regional anesthesia equipment. In Brown D, ed. *Atlas of Regional Anesthesia*, 2nd ed. Philadelphia, PA: Saunders; 1999:5-6.
 20. Ereth MH, Stubbs SE, Lennon RL. Bronchoscopic pharmacology and anesthesia. In: Prakash USB, ed. *Bronchoscopy*, 1st ed. Philadelphia, PA: Lippincott-Raven; 1997:98.
 21. Vasoconstrictors: Eye, ear, nose, and throat (EENT) preparations. In McEvoy GK, ed. *American Hospital Formulary Service Drug Information (2001)*. Bethesda, MD: American Society of Health-System Pharmacists; 2001:2733-2734.
 22. Spraycar M, ed. *Stedman's Medical Dictionary*, 26th ed. Baltimore, MD: Williams & Wilkins; 1995.
 23. Kunda P, Kutralam S, Ravishankar M. Local anesthesia for awake fiberoptic nasotracheal intubation. *Acta Anaesthesiol Scand* 2000;44:511-516.
 24. Mostafa SM, Murthy BVS, Hodgson CA, Beese E. Nebulized 10% lignocaine for awake fiberoptic intubation. *Anaesth Intensive Care* 1998;26:222-223.
 25. Chung DC, Mainland PA, Kong AS. Anesthesia of the airway by aspiration of lidocaine. *Can J Anaesth* 1999; 46:215-219.
 26. Stubbs SE, McDougall JC. Preparation of the patient for bronchoscopy. In: Prakash UBS, ed. *Bronchoscopy*, 1st ed. Philadelphia, PA: Lippincott-Raven; 1997:107-108.
 27. Prakash UBS, Cortese DA, Stubbs SE. Technical solutions to common problems in bronchoscopy. In: Prakash UBS, ed. *Bronchoscopy*, 1st ed. Philadelphia, PA: Lippincott-Raven; 1997:113.
 28. Glossopharyngeal block. In Brown D, ed. *Atlas of Regional Anesthesia*, 2nd ed. Philadelphia, PA: Saunders; 1999:205-208.
 29. Superior laryngeal block. In Brown D, ed. *Atlas of Regional Anesthesia*, 2nd ed. Philadelphia, PA: Saunders; 1999:211-212.
 30. Gotta AW, Sullivan CA. Anaesthesia of the upper airway using topical anaesthetic and superior laryngeal nerve block. *Br J Anaesth* 1981;53:1055-1058.
 31. Translaryngeal block. In Brown D, ed. *Atlas of Regional Anesthesia*, 2nd ed. Philadelphia, PA: Saunders; 1999:215-216.
 32. Airway block anatomy. In Brown D, ed. *Atlas of Regional Anesthesia*, 2nd ed. Philadelphia, PA: Saunders; 1999:197-199.
 33. Benzodiazepines. In Stoelting RK, ed. *Pharmacology and Physiology in Anesthetic Practice*, 2nd ed. Philadelphia, PA: Lippincott; 1991:121.
 34. Intravenous anesthetics. In Stoelting RK, Miller RD, eds. *Basics of Anesthesia*, 3rd ed. New York, NY: Churchill Livingstone; 1994:67.