

An unusual conduit for a paediatric tracheostomy tube exchange

BS Küsel^{a*} and RE Hodgson^b

^aAnaesthesia Registrar, University of KwaZulu Natal, Durban, South Africa

^bInkosi Albert Luthuli Central Hospital, Durban, South Africa and Department of Anaesthesia and Critical Care, Nelson R Mandela School of Medicine, Durban, South Africa

*Corresponding author, email: belinda.kusel@gmail.com

This case report demonstrates the challenges of the paediatric airway, and useful, practical solutions in the management of tracheostomies in children. A six-year-old child underwent a tracheostomy, where an inappropriately large tracheostomy tube was inserted. The choice was guided by the internal diameter (ID) of the tracheostomy tube (TT) rather than the external diameter of the TT (which is much larger than the external diameter (ED) of an endotracheal tube (ETT)). The reduced diameter of the paediatric airway led to complications following the tracheostomy insertion.

The TT needed to be exchanged to a smaller size to provide reliable access to the trachea. Access to the airway had to be maintained during the exchange process, as there was extensive head and neck swelling, which would have made re-intubation from above impossible. The conduit chosen for the tube exchange was a section of tubing from a high-capacity fluid administration set. Fixation of the tube was difficult, but finally achieved by a modified cable tie.

Tracheostomy is a potentially hazardous procedure in children. The correct size TT needs to be selected with consideration of the ED rather than ID of the TT. This case report also demonstrates the utility of the tubing of a high-capacity fluid administration set for TT exchange and the use of a modified cable tie for fixation of the ETT.

Keywords: airway management, anaesthesia, exchange catheters, paediatric tracheostomy, tracheostomy tube exchange

Introduction

The paediatric airway presents a number of challenges to anaesthesiologists, in both the intensive care unit (ICU) and the operating room (OR). A child has a reduced airway diameter, which limits the number of airway devices available for management of the paediatric airway and predisposes the child to airway obstruction with repeated airway instrumentation due to mucosal oedema.¹

The child's age determines the size of endotracheal tubes (ETTs) and tracheostomy tubes (TTs) to use. However, this requires knowledge and understanding of how these tube sizes are labelled. This case report serves to draw attention to these challenges and provide some practical solutions.

Case report

A six-year-old boy was referred to the Inkosi Albert Luthuli Central Hospital (IALCH) trauma intensive care unit (TICU) from his base hospital following a pedestrian vehicle accident. He had multiple injuries, including a head injury, bilateral lung contusions and a blunt abdominal injury. He underwent a laparotomy at the base hospital, where a splenectomy was performed for a grade 5 splenic injury. A liver laceration was also found at laparotomy; this was managed conservatively. He was referred to the TICU after the laparotomy, primarily for further management of the head injury.

The child arrived at IALCH TICU with a size 6.0 ETT, which had been inserted at the base hospital. Gas exchange on lung protective ventilator settings was adequate and he was haemodynamically stable. A chest X-ray revealed bilateral lung contusions and a fractured left clavicle. A CT scan of the brain showed a diffuse head injury with a small subarachnoid haemorrhage which required intracranial pressure (ICP)

monitoring. The patient was admitted to the TICU for ventilation and monitoring of his neurological function.

His TICU stay was complicated by a ventilator-associated pneumonia (VAP) caused by *Moraxella catarrhalis*, which was treated with amoxicillin-clavulanate. His GCS remained 6T (E1M5VT). Owing to this ongoing significant neurological and pulmonary dysfunction, a decision was made on Day 11 of TICU care to perform a tracheostomy.

An open tracheostomy was performed in theatre, where a size 6.0 TT was inserted. No complications were noted during the surgery and the child was returned to TICU in a stable condition.

About six hours after surgery the patient desaturated in the TICU. Surgical emphysema was noted over his chest and neck. This worsened over the next few hours to include his face and abdomen. The child had bilateral pneumothoraces on chest X-ray, requiring intercostal drains (ICD), which led to a transient improvement in the oxygenation.

The following day it was noted that ventilation was becoming increasingly difficult. The child had two episodes of desaturation, with saturations ranging between 60% and 70%, which improved with manual ventilation. However, the oxygenation remained poor, the pO₂ on 60% FiO₂ was 8.4 kPa. The child was ultimately only ventilated in a position of extreme extension of the head with rotation to the right. Any other position would result in decreased tidal volumes and desaturation. Specialists from anaesthesiology and cardio-thoracic surgery were consulted for their opinions.

A fibre-optic bronchoscopy was done by a specialist anaesthesiologist via the TT. Visibility was impaired by

secretions, but the tip of the tracheostomy tube was noted to be extra-tracheal. The defect was in the antero-lateral tracheal wall 1.5 cm proximal to the carina, most likely from the previous tracheostomy procedure. The TT needed to be exchanged to a smaller tube to allow reliable access to the trachea and to prevent further injury to the trachea. This presented the anaesthesiologist with a great challenge as access to the airway had to be maintained during the exchange process. There was extensive head and neck swelling, which would have made re-intubation from above impossible. An Aintree catheter mounted on a fibre-optic scope was not available for this case and would probably have been of limited use as the size would have been too large to advance through the TT.

A few options were assessed for the tube exchange as shown in Figure 1:

1. A size 5.0 ETT: this could be passed over the fibre-optic scope (FOS) into the trachea. However, after removal of the FOS the cuff could not be sufficiently inflated to allow subsequent ventilation. The 5.0 ETT could thus not be used in exchange for the 6.0 tracheostomy tube, which was left in situ and the 5.0 ETT removed.
2. A nasogastric tube (NGT) was tried but the lumen of the largest NGT available was too narrow for the FOS so the NGT could not be reliably passed into the trachea.
3. The tubing of a high-capacity fluid administration (HCFAS) set was found to have sufficient internal diameter to fit the FOS but had a small enough external diameter to allow passage of a size 6 endotracheal tube. A size 6 ETT was measured and a length of HCFAS twice this length was cut. The end was bevelled at approximately 30 degrees to minimise the risk of hook-up during passage over the FOS.

A 40 cm section of the HCFAS was passed over the FOS. The FOS was advanced into the trachea and the HCFAS tubing advanced over the FOS into the trachea. Tracheal position was confirmed by advancing the FOS again to visualise the tracheal rings. The FOS was then removed and a size 6.0 ETT then passed over the HCFAS tubing. Ventilation via the size 6.0 ETT was confirmed by bronchoscopy and capnography. Had passage of the 6.0 ETT failed, oxygen could have been insufflated by connecting the HCFAS tubing to a bag-valve resuscitator using a 5.5 ETT connector.

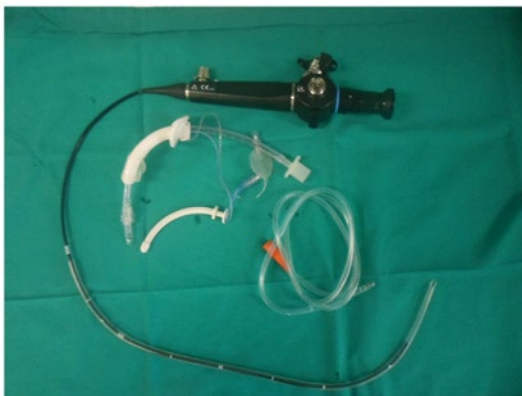

Figure 1: Conduits considered for tube exchange for a size 6 tracheostomy tube: size 5 ETT in size 6 tracheostomy tube, nasogastric tube and high-capacity fluid administration set tubing.

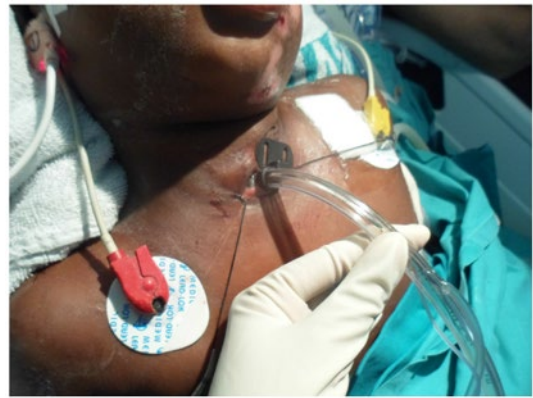

Figure 2: ETT secured with a modified cable tie.

The ETT could only be advanced into the neck incision so far as to allow cuff sealing. Any further advancement resulted in right endobronchial intubation. The 6.0 ETT was securely fixed with a modified cable tie, which is currently under development as a tube fixation device that minimised movement of the ETT (Figure 2).

After the tube exchange ventilation improved. There were still decreased breath sounds over the right side of the chest and on a subsequent chest X-ray a collapsed right lung was noted (Figure 3), which was re-expanded with physiotherapy and suctioning. The cardio-thoracic surgeon performed a fibre-optic bronchoscopy on the following day. No tracheal lesion was noted, but visibility was impaired by secretions. Multiple mucous plaques were suctioned from the right main bronchus, which further improved ventilation.

Two further fibre-optic bronchoscopies were done in the following week. Both showed only secretions occluding the right main bronchus. His ventilation improved slowly over the next two weeks.

On his 27th day in the ICU the child was stable enough for a rigid bronchoscopy in theatre. After induction of anaesthesia with propofol and alfentanil, a propofol infusion was started and further alfentanil boluses (5–10 mcg/kg) were given as needed. The cords were inspected but were swollen, and the bronchoscope could not be passed through the cords without causing trauma to the cords and the upper airway. The endotracheal tube was removed from

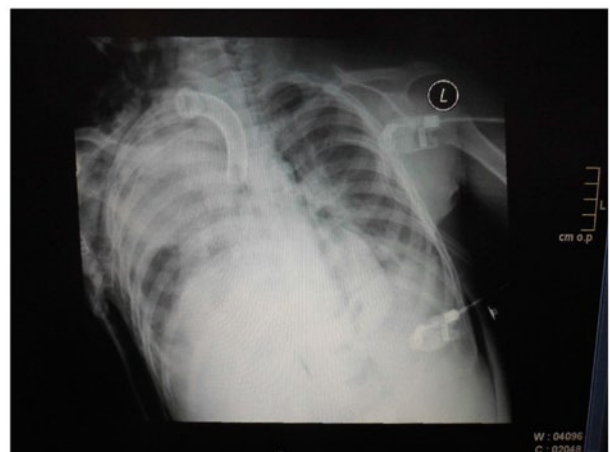


Figure 3: Chest X-ray following the tracheostomy tube insertion.

Table 1: Comparison of internal and external diameters of endotracheal and tracheostomy tubes (<http://www.covidien.com/rms/products/tracheostomy/adult-tracheostomy&product=1>, accessed 18 August 2014)

Size	Endotracheal tube		Tracheostomy tube	
	ID (mm)	OD (mm)	ID (mm)	OD (mm)
4	4.0	5.4	5.0	9.4
6	6.0	8.2	6.4	10.8
8	8.0	11.0	7.6	12.2

the tracheostomy site and a size 6 bronchoscope was inserted through the tracheostomy. A large amount of necrotic debris was cleared from the mid-trachea and a size 5 cuffed tracheostomy tube was inserted into the trachea. The tip of the TT was noted to be below the damaged part of the trachea; the distal airway and carina appeared normal.

The child showed further signs of improvement following the exchange of tracheostomy. He was discharged to his base hospital on day 39 of TICU care, breathing spontaneously via a T-piece. His GCS had improved to E4M6VT.

Discussion

Tracheostomy is a far less commonly performed procedure in children than in adults. The most common indication for tracheostomy in children is prolonged ventilation secondary to respiratory or neuromuscular disease.² Tracheostomies are technically challenging in children, due to anatomical differences between children and adults.

While a TT size in an adult is usually the same size as the ETT, the same is definitely not true in children as illustrated by this case. The internal diameter of a tracheostomy tube is usually similar to the internal diameter of an endotracheal tube of the same size. However, the external diameter of a TT is usually much wider (Table 1).

The diameter and length of the TT to be used need to be carefully planned prior to the tracheostomy. The length and diameter of the TT may also vary between different manufacturers. The TT needs to be large enough to allow for clearance of secretions; however, if the diameter is too large it can injure the mucosa leading to necrosis and tracheal injury. Behl et al. did a retrospective study to generate a formula to calculate the size of tracheostomy to use for children. Age was a reliable predictor for tracheostomy size. The formula that can be used to calculate the inner diameter of the TT is: ID (mm) = age yr/3 + 3.5.³

This child was initially intubated with a size 6.0 ETT with an internal diameter (ID) of 6 mm and an external diameter (ED) of 8.2 mm. By contrast, while the internal diameter of a size 6 tracheostomy tube is 6.4 mm, the ED is 10.8 mm, which is similar to the ED of a size 8.0 ETT and well beyond the capacity of the trachea of a six-year-old boy. According to the Behl formula,³ the child should have had a 5.0 or 5.5 tracheostomy tube inserted. The choice of the size of the tracheostomy tube was guided by the internal diameter of the tracheostomy tube (which is similar to that of an endotracheal tube of the same size) rather than the external diameter of the tube (which is much larger than that of an endotracheal tube).

Tracheostomies often lead to complications in children. Up to 43% of children in one study had a serious complication.⁴ This TT had caused trauma to the child's trachea, leading to bilateral pneumothoraxes.

The tube needed to be exchanged, to avoid further injury to the trachea and to allow ventilation. This was challenging as access from above was not possible due to extensive head and neck swelling because of acute surgical emphysema. Furthermore, access to the airway had to be maintained during the exchange process. In an adult this would be managed by means of an Aintree catheter, mounted on a FOS and placed into the trachea. The tracheostomy tube could be exchanged over the catheter. Unfortunately an Aintree catheter was not available for this case and would probably been of limited use. Aintree catheters generally only allow exchange of size 7.0 or above ETTs.

The conduit that was finally chosen was a section of tubing from a HCFAS, which allowed passage of a FOS and could be used to exchange the tracheostomy tube with a size 6.0 ETT.

Due to the short length of trachea between the tracheal defect and carina, fixation was problematic but finally achieved by a modified cable tie, under development as a tube fixator. This allowed fixation of the tube securely to the neck by means of tapes and sutures.

Conclusion

Tracheostomies are potentially hazardous procedures in children. This case report demonstrates the challenges of the paediatric airway, and useful, practical solutions in the management of tracheostomies in children. The reduced diameter of the paediatric airway led to complications following the tracheostomy insertion. The correct size TT needs to be selected, with consideration of the ED and the ID of the TT. Subsequent exchange of the TT over a FOS may be difficult due to the large ED of the current generation Aintree catheter. This report demonstrates the utility of the tubing of a high-capacity fluid administration set for TT exchange.

References

1. Cote CJ. The difficult paediatric airway. *South Afr J Anaesth Analg.* 2012;18(5):230–9.
2. Hadfield PJ, Lloyd-Faulconbridge RV, Almeyda J, et al. The changing indications for paediatric tracheostomy. *Int J Pediatr Otorhinolaryngol.* 2003 Jan;67(1):7–10. [http://dx.doi.org/10.1016/S0165-5876\(02\)00282-3](http://dx.doi.org/10.1016/S0165-5876(02)00282-3)
3. Behl S, Watt JW. Prediction of tracheostomy tube size for paediatric long-term ventilation: an audit of children with spinal cord injury. *Br J Anaesth.* 2005 Jan;94(1):88–91.
4. Carr MM, Poje CP, Kingston L, et al. Complications in pediatric tracheostomies. *Laryngoscope.* 2001 Nov;111(11 Pt 1):1925–8.

Received: 30-09-2014 Accepted: 12-02-2015